

Intravenous methylprednisolone in patients with episodic cluster headache non-responders to oral steroids: results from an observational, interventional, single-center study

Elisa Rubino,^{1,2} Fausto Roveta,¹ Andrea Marcinnò,¹ Fabio Ferrandes,¹ Elisa Maria Piella,¹ Innocenzo Rainero^{1,2}

¹Rita Levi Montalcini Department of Neuroscience, University of Turin; ²Headache Center, Department of Neuroscience and Mental Health, Città della Salute e della Scienza University Hospital, Turin, Italy

ABSTRACT

Background: Verapamil is the drug of choice in the prophylaxis of episodic cluster headache (ECH), and oral corticosteroids are frequently prescribed as concurrent bridging therapy. Approximately 25% of the patients do not respond to oral treatment. The aim of this study was to assess safety and efficacy of high dose intravenous methylprednisolone (MPD) in ECH patients who had not responded to combined oral therapy with prednisone and verapamil.

Methods: Forty-four ECH patients – non responders to oral therapy – were treated with intravenous MPD (500 mg/day for 5 days) and verapamil during cluster headache active periods. No serious adverse event was reported.

Results: After 5 days of intravenous therapy, the 24-hour frequency of cluster headache attacks significantly decreased. Sixty-eight percent of patients became headache-free, and 25% experienced a reduction of more than 50% in daily attacks. No clinical benefit was reported in the remaining three patients.

Conclusions: Our study shows that intravenous MPD is a safe, effective, and reproducible treatment for ECH patients not responding to oral therapy.

Key words: cluster headache, episodic cluster headache, methylprednisolone, verapamil, bouts.

Introduction

Cluster headache (CH) is a relatively rare but disabling medical condition (1). The disease is characterized by the occurrence of attacks of severe unilateral periorbital pain accompanied by ipsilateral autonomic signs. CH exhibits a circadian rhythmicity of the attacks, which are interspersed by periods of complete remission in most individuals. The burden imposed by CH, encompassing loss of employment, direct and indirect costs, and disability, is of paramount importance (2). Many treatment options for CH are available but there are few controlled randomized clinical studies.

The majority of patients with episodic cluster headache (ECH) requires preventive therapies. Verapamil, with a mean daily dose of 360 mg, is considered the treatment of choice in the prophylaxis of ECH according to national and international guidelines (3-5). In open-label and placebo-controlled studies, approximately 70% of cluster headache patients showed substantial improvement with verapamil (6-8). However, the full therapeutic effect may be expected not before two-three weeks. Therefore, add-on prophylactic drugs (transitional or bridging therapy) are valuable in rapidly suppressing attacks at the onset of a cluster active period (bout). Most studies on bridging therapies were performed with corticosteroids, administered as oral or intravenous medication, or injected into the greater occipital nerves (9-11). Several open studies and case series have been published and confirmed the clinically well-known efficacy of steroids given under different therapeutic regimens. Prednisone (50-100 mg *per os* daily) or dexamethasone (24 mg *per os* daily) are usually employed for the first 10 to 14 days. Recently, a large German placebo-controlled trial randomized 118 patients with ECH to receive either 100 mg of oral prednisone for 5 days followed by tapering the dose or a placebo. Additionally, all participants

received an increasing dose of oral verapamil for long-term prevention. The study results revealed that patients in the prednisone group showed a mean of 7.1 attacks in the first week, while those in the placebo group had 9.5 attacks (11).

In clinical practice there is frequently a reduction in CH episodes with the use of oral corticosteroids, and these are generally reduced and discontinued when preventive agents reach therapeutic levels. However, some patients with ECH may not respond to oral therapy or may progress to the chronic form of the disease. There is currently limited evidence on treatment options in patients who do not respond to oral therapies.

The main objective of this study is to describe the clinical results of the use of intravenous methylprednisolone therapy after oral therapy failure in a single-centre cohort of patients with episodic cluster headache.

Results

Forty-four episodic CH patients (36 males, 8 females; mean age 38.8±10.4 years) were included in the study, and forty-four headache active periods were treated using the intravenous methylprednisolone protocol.

The age of onset of cluster headache onset was 33.1±9.9 years, while the duration of disease was 13.3±8.5 years. Detailed patients' clinical characteristics are shown in **Table 1**.

Efficacy outcome

Frequency of attacks. Following the completion of the intravenous methylprednisolone (MPD) infusion, there was a signifi-

cant reduction in the 24-hour frequency of cluster headache attacks. At baseline, the number of attacks per day at was 4.0 ± 1.7 (4.1 ± 1.6 in males, 3.7 ± 2.5 in females). After 5 days of intravenous therapy, the number of attacks per day decreased to 0.51 ± 1.2 ($p < 0.001$). In 93.2% (41 out of 44) of the bouts, patients demonstrated a clinical response, with 68.2% (30 out of 44) of episodic cluster headache patients being headache-free. Additionally, in 25% (11 out of 44) of the bouts, there was a reduction of more than 50% in the number of daily attacks. No clinical benefit was reported in the remaining three patients (Figure 1).

All ECH patients who responded to MPD therapy reported a reduction in the intensity and frequency of headache attacks from the second day of intravenous therapy, with 63.6% of the considered bouts interrupted within 48 hours. At discharge, mean dosage of verapamil was 401.8 mg/daily (range 160-720 mg), and the treatment was well tolerated without significant cardiac effects.

Recurrence of cluster headache active periods. At 3-month follow-up visits, the recurrence of cluster headache was observed in 14% of patients, whereas at 9 and 12 months the recurrence was 29% and 35% respectively (Figure 2), likely due the classical periodicity of cluster headache in the recruited patients (1-2 bouts/year). Patients experienced a shortening of their usual predicted bout length of 2.6 weeks, and none experienced a lengthening of their bout.

Adverse events. No serious adverse event was reported during the treatment. Minor adverse events were reported by 18.9% of patients with ECH, and none of these events led to the discontinuation of the protocol therapy. Mild adverse events included skin flushes during infusion, an elevation in blood pressure, gastric symptoms controlled by omeprazole/pantoprazole, hyperglycemia, insomnia, and agitation.

Long-term adverse events. No serious long-term adverse event was reported. Long-term adverse events at 12 months were reported by 11.3% of ECH patients, and included worsening of osteoporosis (two patients), hypertension (one patient), hypercortisolism (one patient), impaired glucose tolerance (one patient).

Discussion

The findings of our study suggest that high dosage intravenous methylprednisolone, in association with oral verapamil, is a safe, effective, and reproducible treatment in patients with episodic cluster headache who do not respond to oral therapy. After the five days of intravenous therapy, approximately 80% of the patients experienced a significant relief of symptoms. Notably, the same percentage of patients reported no cluster headache attacks in a six-month period after treatment. Given the acceptable tolerability profile, this approach can play a valuable role in the comprehensive management of cluster headache.

Table 1. Baseline demographic and clinical characteristics of patients with episodic cluster headache.

	CH patients	Males	Females
Total	44	36	8
Age at onset (mean \pm SD, years)	33.1 \pm 9.9	36.6 \pm 12.5	29.7 \pm 4.5
Duration of disease (mean \pm SD, years)	13.3 \pm 8.5	13.1 \pm 8.7	16.5 \pm 2.1
Number of attacks per day at baseline	4.0 \pm 1.7	4.1 \pm 1.6	3.7 \pm 2.5
Frequency of bout per year (mean \pm SD)	1.3 \pm 0.6	1.4 \pm 0.6	1.3 \pm 0.6
Mean duration of bout (mean \pm SD, weeks)	5.6 \pm 3.3	6.1 \pm 4.3	5.1 \pm 2.3
Smoking	30/44	26/36	4/8

CH, cluster headache; SD, standard deviation.

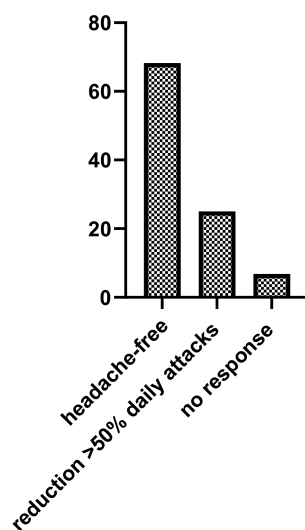


Figure 1. Clinical outcome of cluster headache attacks after 5 days of intravenous methylprednisolone, in percentage.

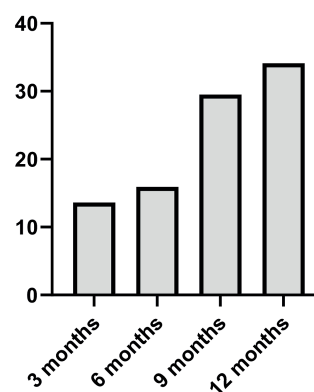


Figure 2. Recurrence of cluster headache attacks at 3, 6, 9 and 12 months, in percentage.

The use of high dose intravenous MPD for treating CH attacks was first reported in 1998 (12). A patient with ECH unresponsive to oral 100 mg prednisolone for 2 weeks was prescribed with 500 mg of intravenous MPD with a remarkably positive response. A few years later, Mir *et al.* treated 14 patients with ECH with 250-mg boluses of MPD on 3 consecutive days and found that, during the active phase of the disease, attacks were significantly less frequent in patients treated with MPD boluses than in those treated with other medications (13). Antonaci *et al.* investigated the effects of a single pulse of MPD, at the dose of 30 mg/kg body weight, in ECH patients. A significant reduction in CH attacks was observed, but only 3 out of 13 patients achieved a complete headache remission, and the treatment proved to be ineffective in maintaining complete clinical remission (14). A case report showed the efficacy of high dose MPD associated with high dose of verapamil being effective also in a patient with chronic CH (15). In a further study, 6 ECH patients were treated with a single 250-500 mg bolus of MPD, resulting in a significant reduction of the headache attacks (16). Nevertheless, some of the patients needed a second treatment, in accordance with a dose-dependent effect. Our study in a large group of ECH patients further expands previous clinical studies, suggesting that a 5-day MPD intravenous treatment schedule could more effective than a single pulse treatment.

To date, randomized controlled trials showed that in cluster headache transitional oral treatment with steroids and suboccipital steroid injections rapidly reduce the number of attacks while awaiting the onset of preventive drug effect. In a recent study conducted by Obermann *et al.*, compelling evidence was presented in support of the use of oral steroids as a transitional treatment for ECH (11). The study involved patients currently experiencing an active bout of episodic cluster headache, randomly assigned in a double-blind manner. The participants received either 100 mg of oral prednisone for 5 days, followed by a tapering regimen of 20 mg every 3 days (totaling 1100 mg over 17 days; n=53), or a placebo (n=56). The oral steroids were provided as an additional treatment alongside oral verapamil, which was initiated at 40 mg three times per day, with subsequent increases every 3 days by 40 mg to a maximum of 360 mg per day. This study contributes robust and long-awaited evidence supporting the efficacy of oral steroids as a transitional treatment option for episodic cluster headache when combined with oral verapamil.

Our study findings indicate that the use of methylprednisolone iv in managing ECH that is unresponsive to oral therapy yields substantial benefits. These benefits include a notable decrease in the number of attacks and cluster days, with patients also demonstrating a high response rate characterized by a complete cessation of attacks. Therefore, the main finding of our study is that patients not responding to corticosteroids oral therapy might benefit of higher dose of steroids administered intravenously.

Recently, the European Academy of Neurology Guidelines have recommended the use of steroids in cluster headache, suggesting a minimum of 100 mg prednisone (or an equivalent corticosteroid) administered orally or up to 500 mg intravenously per day over a 5-day period (17). Thence, the guideline suggests that patients with ECH should be treated with high-dose corticosteroid therapy. Considering this recommendation, future studies could explore potential differences in clinical response between oral and intravenous administration of corticosteroids in patients with ECH. Such investigations could provide valuable insights into the comparative effectiveness and benefits of these two modes of administration in managing this painful condition.

The pharmacological mechanisms underlying the action of

corticosteroids in the treatment of cluster headache are not yet definitively established. It is well known that corticosteroids enter the cell and bind to a specific receptor. The corticosteroid/corticosteroid receptor complex then enters the nucleus, where it interacts with corticosteroid-responsive elements of various genes and multiple transcription factors (18). One well-documented effect is the inhibition of the production of various inflammation-associated molecules, including cytokines, chemokines, arachidonic acid metabolites, and adhesion molecules. At high dosage, corticosteroids induce immunosuppression, decreasing the function and numbers of lymphocytes, including both B cells and T cells (19). Furthermore, a study showed that intravenous MPD significantly decreases plasma concentrations of calcitonin gene-related peptide while increases melatonin metabolites in urine of ECH patients (20). The combination of the immunomodulatory and neuroendocrine effects is the most likely explanation of our data.

Conclusions

There are some limitations in our study that deserve mention and suggest caution in interpreting the results. Firstly, this is an open-label study, and it lacks a placebo-controlled group. Additionally, the clinical data of the MPD study were collected using a retrospective strategy. However, the substantial number of ECH patients involved in our study, the number of cluster headache active periods examined, and the long follow-up period significantly support our results.

In conclusion, our study provides clinical data suggesting a role for high-dose intravenous corticosteroids in the therapy of cluster headache attacks. Placebo-controlled studies are warranted to evaluate the clinical relevance of our data.

Materials and Methods

This was an observational, single-center, interventional, therapeutic study conducted at the Headache Centre of the *Rita Levi Montalcini* Department of Neuroscience of the University of Torino (Italy) between 2013 and 2022. Eligible patients were males and females aged between 18 and 65 years fulfilling the International Classification of Headache Disorders II and III diagnostic criteria for episodic cluster headache at the time of inclusion (21, 22).

Comprehensive physical and neurological examinations were conducted. At the onset of each cluster active period, a combination therapy with verapamil 40-80 mg three times daily, and oral prednisone 60 mg daily was prescribed. Electrocardiograms and vital signs were obtained prior to the administration of verapamil. Study participants were required to be within their bout for no longer than two weeks. Patients with ECH who did not respond to the initial two weeks of oral therapy (with attacks occurring more than once every other day) were admitted to the study. They underwent treatment with intravenous methylprednisolone 500 mg/day for 5 days, concurrently with verapamil administered orally three times a day. Intravenous MPD was followed by oral prednisone with a tapering course, with a reduction of oral prednisone from 50 mg with halving of the dosage every 3 days (25 mg, 12.5 mg) for 9 days. Patients with contraindications to steroids or verapamil, those taking anticoagulants, or those with a known bleeding disorder were excluded from the study.

Patients with ECH who were already on verapamil received a prescription for escalation up to 720 mg daily, as tolerated. Verapamil was gradually reduced over two weeks after headache attacks disappearance in patients assuming ≤ 320

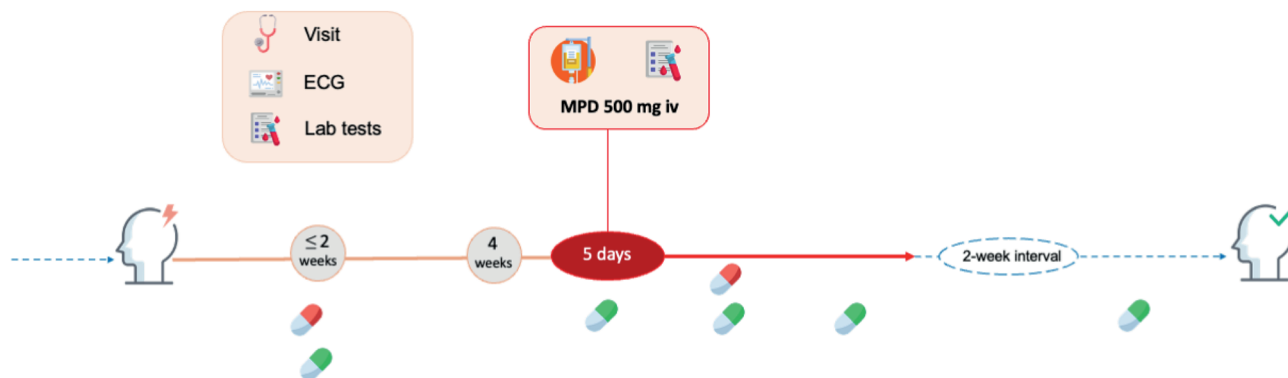


Figure 3. Flowchart illustrating the study design. During the first two weeks of a cluster headache (CH) active period (represented by a continuous line), eligible patients were prescribed steroids and verapamil. If the frequency of attacks remained above once every other day following two weeks of oral therapy, patients were admitted for 5 days of intravenous methylprednisolone (MPD), followed by an oral prednisone tapering regimen. If no CH episodes occurred for two weeks, patients were instructed to slowly taper off verapamil until it was completely discontinued. Dashed lines indicate the CH remission period. The red pill represents oral prednisone, and the green pill oral verapamil.

mg daily, and over three-four weeks in patients assuming more than 320 mg/daily, depending on the dose.

Acute treatment options with subcutaneous sumatriptan or intranasal oxygen was permitted, as needed. Safety parameters included recording and examining a 12-lead electrocardiogram to exclude bradycardia/tachycardia or arrhythmia. Daily measurements were taken for resting blood pressure and heart rate. At baseline, routine laboratory tests were performed, with additional tests performed as necessary during the infusion therapy. All the patients involved in the study were followed, at three-month intervals, for a twelve-month period. At each visit, clinical data were collected. **Figure 3** illustrates the design of the study. All participants provided informed consent to the clinical study.

Statistical analysis. Statistics and graphics were obtained using GraphPad Prism 10.0.1. Continuous variables were presented as means \pm standard deviations, and categorical ones as counts and percentages. Differences of continuous data between groups were studied by the unpaired *t*-test or its non-parametric variant (Mann-Whitney test). A two-tailed *p*-value of <0.05 was considered significant.

References

- Russell MB. Epidemiology and genetics of cluster headache. *Lancet Neurol* 2004;3:279-283.
- Gaul C, Finken J, Biermann J, Mostardt S, Diener HC, Müller O, et al. Treatment costs and indirect costs of cluster headache: a health economics analysis. *Cephalalgia* 2011;31:1664-72.
- Sarchielli P, Granello F, Prudenzano MP, Pini LA, Guidetti V, Bono G, et al. Italian guidelines for primary headaches: 2012 revised version. *J Headache Pain* 2012;13:S31-70.
- May A, Leone M, Afra J, Linde M, Sándor PS, Evers S, et al. EFNS guidelines on the treatment of cluster headache and other trigeminal-autonomic cephalalgias. *Eur J Neurol* 2006;13:1066-77.
- Robbins MS, Starling AJ, Pringsheim T, Becker WJ, Schwedt TJ. Treatment of cluster headache: the American Headache Society Evidence-Based Guidelines. *Headache* 2016;56:1093-106.
- Evers S. Pharmacotherapy of cluster headache. *Expert Opin Pharmacother* 2010;11:2121-7.
- Leone M, D'Amico D, Frediani F, Moschiano F, Grazi L, Attanasio A, Bussone G. Verapamil in the prophylaxis of episodic cluster headache: a double-blind study versus placebo. *Neurology* 2000;54:1382-5.
- May A, Schwedt TJ, Magis D, Pozo-Rosich P, Evers S, Wang SJ. Cluster headache. *Nat Rev Dis Primers* 2018;4:18006.
- Ambrosini A, Vandenhede M, Rossi P, Aloj F, Sauli E, Pierelli F, et al. Suboccipital injection with a mixture of rapid- and long-acting steroids in cluster headache: a double-blind placebo-controlled study. *Pain* 2005;118:92-6.
- Leroux E, Valade D, Taifas I, Vicaut É, Chagnon M, Roos C, et al. Suboccipital steroid injections for transitional treatment of patients with more than two cluster headache attacks per day: a randomised, double-blind, placebo-controlled trial. *Lancet Neurol* 2011;10:891-7.
- Obermann M, Nägel S, Ose C, Sonuc N, Scherag A, Storch P, et al. Safety and efficacy of prednisone versus placebo in short-term prevention of episodic cluster headache: a multicentre, double-blind, randomised controlled trial. *Lancet Neurol* 2021;20:29-37.
- Cianchetti C, Zudeas A, Marchei F. High-dose intravenous methylprednisolone in cluster headache. *J Neurol Neurosurg Psych* 1998;64:418.
- Mir P, Alberca R, Navarro A, Montes E, Martínez E, Franco E, et al. Prophylactic treatment of episodic cluster headache with intravenous bolus of methylprednisolone. *Neurol Sci* 2003;24:318-21.
- Antonaci F, Costa A, Candeloro E, Sjaastad O, Nappi G. Single high-dose steroid treatment in episodic cluster headache. *Cephalalgia* 2005;25:290-5.
- Zanchin G, Disco C, Mainardi F, Mampreso E, Lisotto C, Maggioni F. High-dose of methylprednisolone and verapamil in chronic cluster headache: a case report. *J Headache Pain* 2012;13:S26.
- Kawada S, Kashihara K, Imamura T, Ohno O. High-dose intravenous methylprednisolone for the prophylactic treatment of cluster headache. *Springerplus* 2013;2:156.
- May A, Evers S, Goadsby PJ, Leone M, Manzoni GC, Pascual J, et al. European Academy of Neurology guidelines on the treatment of cluster headache. *Eur J Neurol* 2023;30:2955-79.
- Ramamoorthy S, Cidowski JA. Corticosteroids. *Rheum Dis Clin N Am* 2016;42:15-31.
- Klehmet J, Staudt M, Ulm L, Unterwalder N, Meisel A, Meisel C. Circulating lymphocyte and T memory subsets in glucocorticosteroid versus IVIG treated patients with CIDP. *J Neuroimmunol* 2015;283:17-22.

20. Neeb L, Anders L, Euskirchen P, et al. Corticosteroids alter CGRP and melatonin release in cluster headache episodes. *Cephalalgia* 2015;35:317-326.
21. Headache Classification Committee of the International Headache Society. The International Classification of Headache Disorders, 2nd edn. *Cephalalgia* 2004;24:160.
22. Olesen, J. Headache Classification Committee of the International Headache Society (IHS) The International Classification of Headache Disorders, 3rd edition. *Cephalalgia* 2018;38:1-211.

Correspondence: Elisa Rubino, Headache Center - Department of Neuroscience "Rita Levi Montalcini", University of Turin, via Cherasco 15, 10126 Torino, Italy. Tel.: +39.011.6334763.
E-mail: elisa.rubino@unito.it

Conflict of interest: the authors declare no potential conflict of interest.

Acknowledgements: the authors thank the patients who participated to the study.

Consent for publication: not applicable.

Availability of data and materials: the datasets used and/or analyzed during the current study are available from the corresponding author upon reasonable request.

Received: 15 January 2024. Accepted: 19 May 2024.

Publisher's note: all claims expressed in this article are solely those of the authors and do not necessarily represent those of their affiliated organizations, or those of the publisher, the editors and the reviewers. Any product that may be evaluated in this article or claim that may be made by its manufacturer is not guaranteed or endorsed by the publisher.

Confinia Cephalalgica 2024; 1:15618. doi:10.4081/cc.2024.15618

©Copyright: the Author(s), 2024. Licensee PAGEPress, Italy

This work is licensed under a Creative Commons Attribution-NonCommercial 4.0 International License (CC BY-NC 4.0).